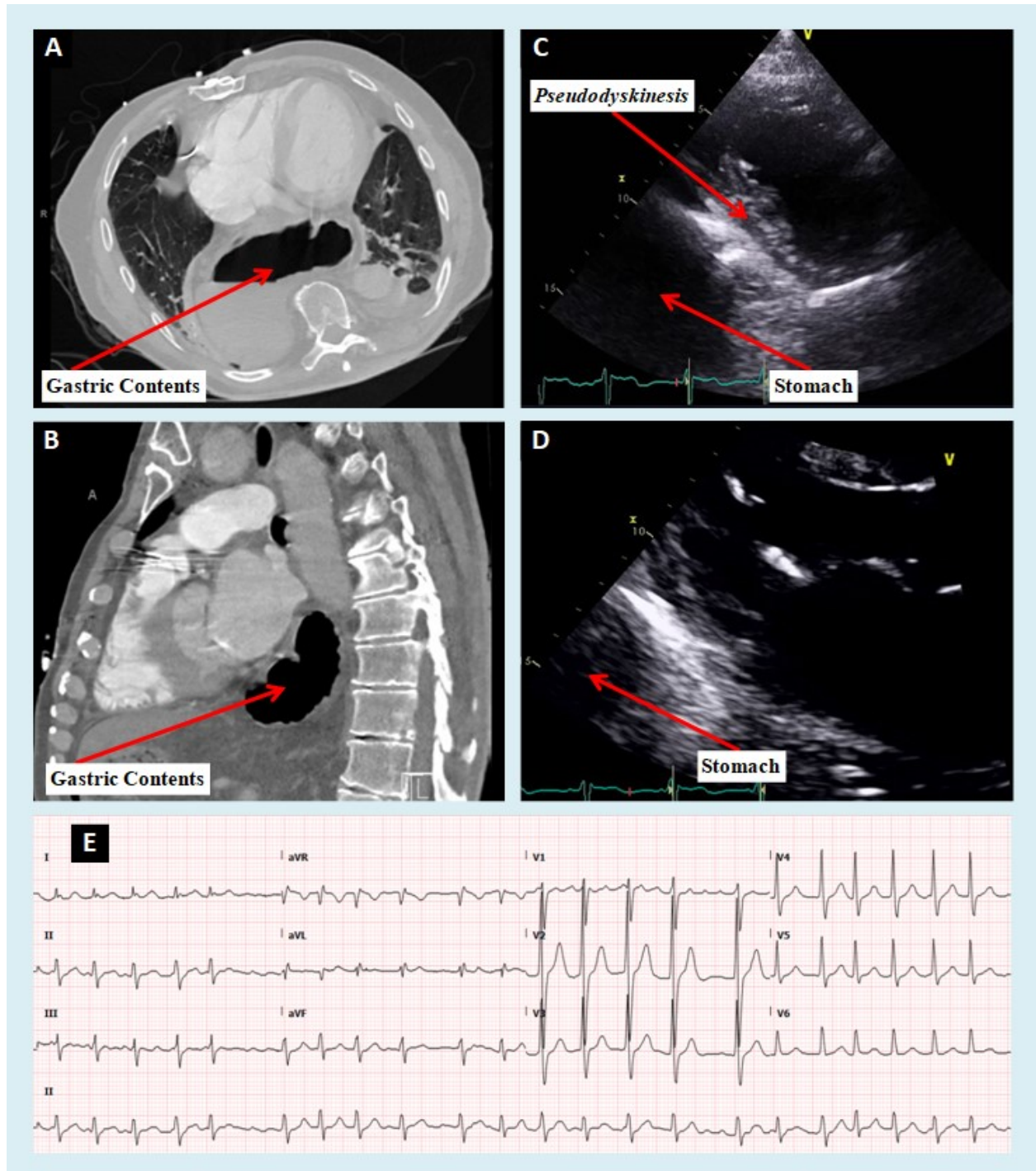


Roemheld’s Gastrocardiac Syndrome: A Gastrocardiology Discipline!

Parks, Alexis, D.O.^a, Mariam Riad, M.D.^a, Mustafeez Ur Rahman, M.D.^a, Rajasekhar Mulyala, M.D.^a
 Nupur Shah, M.D.^a, G. Mustafa Awan, M.D.^a, Christopher Malozzi, D.O.^a, Bassam Omar, M.D., Ph.D.^{a,b}



Description

The above computed tomography scans in the axial (A) and sagittal (B) planes reveal the stomach within the chest cavity impinging on the lungs and heart due to a large hiatal hernia. The 2-D parasternal echocardiography images (short axis, C, and long axis, D) reveal the stomach adjacent to the inferolateral wall of the heart and causing flattening of the inferolateral wall during diastole, also known as pseudodyskinesis. The EKG in panel E reveals atrial fibrillation, a potential result of a large hiatal hernia.

Discussion

The interaction between the stomach and the heart has been known for many years and has been reported to result in variable symptoms which can mimic true cardiac conditions [1].

Hiatal hernias are characterized by the displacement of abdominal contents into the thoracic cavity through an opening in the diaphragm. Hernias can be characterized as type I – IV based on amount of contents that have herniated [2]. Type I hernias involve the displacement of the gastroesophageal junction into the thoracic cavity and are typically asymptomatic or present with reflux type symptoms. Type II-IV hiatal hernias involve displacement of stomach contents and other organs into the thoracic cavity (also known as para-esophageal hernias) and can cause a wide variety of symptoms at time of presentation [3]. In more sizable hernias, there can be evidence of posterior cardiac compression, especially of the inferior and inferolateral left ventricular wall segments, which may cause significant arrhythmia [4]. Hernias with >30% of the stomach protruding into the thoracic cavity are more commonly associated with cardiac complications [5] such as chest pain [6] and dyspnea on exertion [7] secondary to left atrial compression and compression of cardiac inflow structures such as pulmonary veins and coronary sinus. A variety of dynamic electrocardiographic changes [8], have also been associated with hiatal hernias. Complete heart block [9], supraventricular tachycardia [10] and atrial fibrillation [11] have also been reported in the setting of large hiatal hernias,

with symptoms occasional related to food intake [12]. Cardiac symptoms and arrhythmogenesis associated with hiatal hernia typically resolve after surgical [13] or less invasive LINX placement [14] hiatal hernia repair.

Conclusion

Hiatal hernias are not typically included in the probable clinical causes of cardiac arrhythmias and are often missed as a potentially treatable cause of arrhythmogenesis. Large hiatal hernias' association with cardiac presentations, known as Roemheld's gastrocardiac syndrome, is thought to result from local irritation, compression, and localized inflammatory response. Whether hernia treatment or repair can ameliorate a significant portion of the reported cardiac sequelae remains an intriguing question. With the ever growing prevalence of hiatal hernias in the US and worldwide, in addition to other documented interactions between gastroenterologic and cardiac disease, perhaps it is time to consider gastrocardiology as a novel subspecialty field of training in cardiology! [15].

Manuscript submitted March 7 accepted March 15, 2023

a Division of Cardiology. University of South Alabama, Mobile, AL 36617

b Corresponding Author: Bassam Omar, Division of Cardiology, University of South Alabama, 2451 USA Medical Center Dr., Mobile, AL 36617, USA.

Email: bomar@health.southalabama.edu

<https://cardiofellows.com/newsletter-march-2023.html>

References

1. Gesualdo M, Scicchitano P, Carbonara S, et al. The association between cardiac and gastrointestinal disorders: causal or casual link? J Cardiovasc Med (Hagerstown). 2016 May;17(5):330-8.
2. Cha RR. Find Out the Differences by Types of Hiatal Hernia! J Neurogastroenterol Motil. 2020 Jan 30;26(1):4-5.
3. Oleynikov D, Jolley JM. Paraesophageal hernia. Surg Clin North Am. 2015 Jun;95(3):555-65.

4. Gnanenthiran SR, Naoum C, Kilborn MJ, et al. Posterior cardiac compression from a large hiatal hernia-A novel cause of ventricular tachycardia. *HeartRhythm Case Rep.* 2018 May 23;4(8):362-366.
5. Schummer W. Hiatal hernia mimicking heart problems. *BMJ Case Rep.* 2017 Jul 27;2017:bcr2017220508.
6. Khan MZ, Yousaf H, Dahiya DS, et al. Chest Pain: A Relatively Benign Symptom of Type IV Hiatal Hernia. *Cureus.* 2020 Nov 12;12(11):e11459.
7. Mirdamadi SA, Arasteh M. Hiatal hernia: An unusual presentation of dyspnea. *N Am J Med Sci.* 2010 Aug;2(8):395-6.
8. Hokamaki J, Kawano H, Miyamoto S, et al. Dynamic electrocardiographic changes due to cardiac compression by a giant hiatal hernia. *Intern Med.* 2005 Feb;44(2):136-40.
9. Abbood A, Al Salihi H, Parellada J, et al. A Large Intrathoracic Hiatal Hernia as a Cause of Complete Heart Block. *Case Rep Cardiol.* 2021 Jul 9;2021:6697016.
10. Qureshi K, Naeem N, Saleem S, et al. Recurrent Episodes of Paroxysmal Supraventricular Tachycardia Triggered by Dyspepsia: A Rare Case of Gastrocardiac Syndrome. *Cureus.* 2021 Sep 14;13(9):e17966.
11. Malik A, Best K, Singh S, Jaggon KS, et al. Hiatal Hernia: A Possible Trigger for Atrial Fibrillation. *Cureus.* 2021 Oct 18;13(10):e18857.
12. Cristian DA, Constantin AS, Barbu M, et al. Paroxysmal postprandial atrial fibrillation suppressed by laparoscopic repair of a giant paraesophageal hernia compressing the left atrium. *J Gastrointest Liver Dis.* 2015 Mar;24(1):113-6.
13. de Carvalho JPV, Pivetta LGA, Dias ERM, et al. Reversal of unstable atrial fibrillation after surgical correction of hiatus hernia: A case report. *Int J Surg Case Rep.* 2021 Sep;86:106316.
14. Noom MJ, Dunham A, DuCoin CG. Resolution of Roemheld Syndrome After Hiatal Hernia Repair and LINX Placement: Case Review. *Cureus.* 2023 Apr 11;15(4):e37429.
15. Hofmann R, Bäck M. Gastro-Cardiology: A Novel Perspective for the Gastrocardiac Syndrome. *Front Cardiovasc Med.* 2021 Nov 17;8:764478.

KEYWORDS: Gastrocardiac Syndrome; Hiatal Hernia; Gastrocardiology.

Reference this article as:

Parks A, Riad M, Rahman MU, Mulyala R, Shah N, Awan GM, Malozzi C, Omar B. Roemheld's Gastrocardiac Syndrome: *A Gastrocardiology Discipline!* Cardiofel Newslet 2023. March; 6(3):7 – 9.