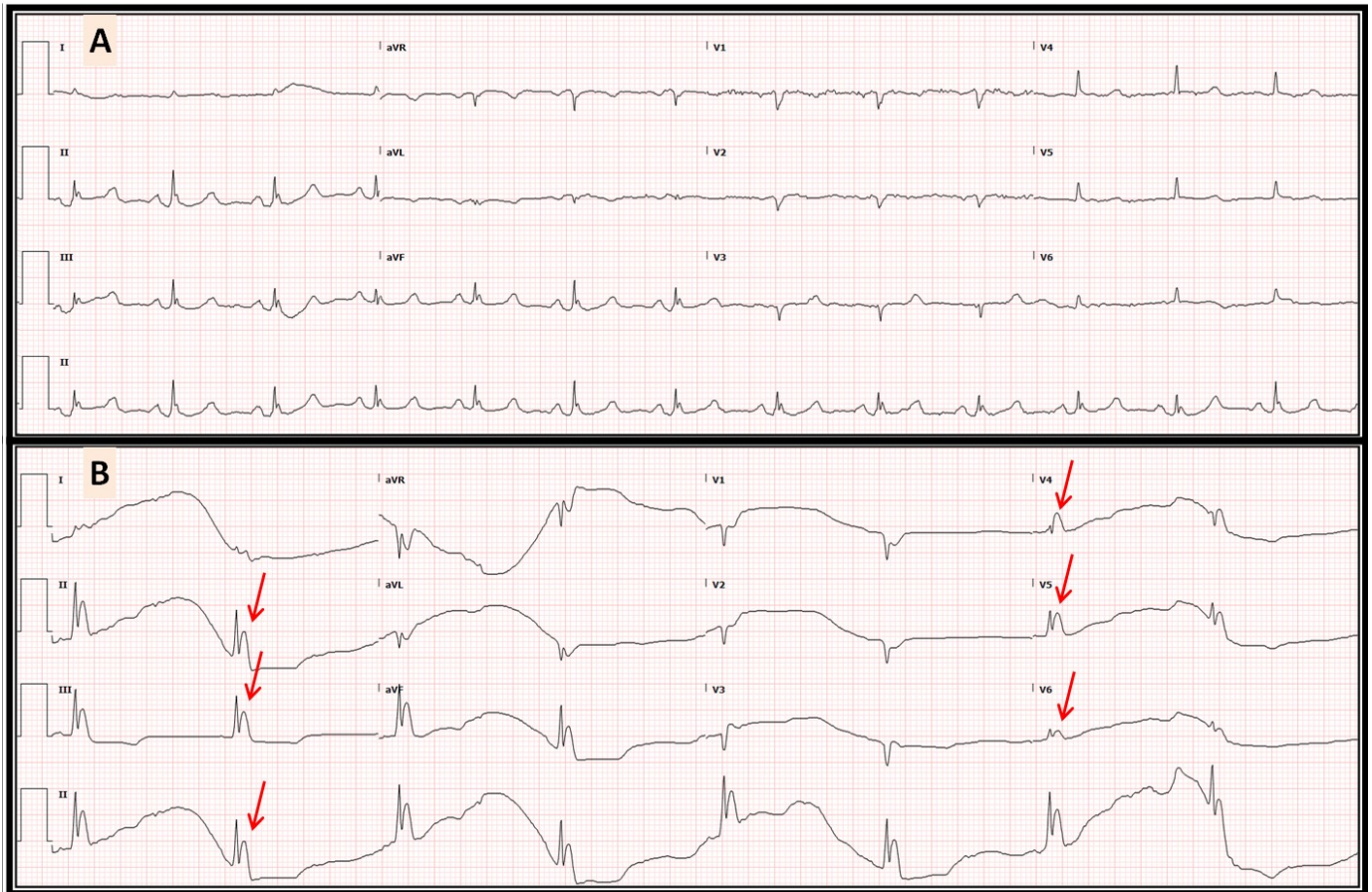


Monstrous Osborn Waves: A Frigid Demise!

Mustafeez Ur Rahman, M.D.^a, Mariam Riad, M.D.^a, Nupur Shah, M.D.^a,

Rajasekhar Mulyala, M.D.^a, Christopher Malozzi, D.O.^a, Bassam Omar, M.D., Ph.D.^{a,b}



Description

The above electrocardiogram (ECG) was obtained in an elderly patient at baseline (A) and during profound hypothermia (B) with documented severe sepsis leading to death. The prominent terminal QRS deflections consistent with Osborn (J) waves are marked with red arrows in the inferolateral leads.

Discussion

Several manifestations of hypothermia on the ECG have been described, including bradycardia and prolonged QT interval as seen in figure B above [1], in addition to prolongation of the PR interval and QRS duration. The terminal blunt deflections of the QRS complex

(spike-and-dome appearance) termed Osborn waves [2] or J waves [3] are the hallmark of hypothermia on EKG. First described by John J. Osborn in 1953 [4], the mechanism of the J-wave remains unclear but appears to be related to a heterogeneous distribution of a transient outward current of the action potential [5].

Manuscript submitted July 18, accepted July 20, 2023
a Division of Cardiology. University of South Alabama,
Mobile, AL 36617

b Corresponding Author: Bassam Omar, Division of
Cardiology, University of South Alabama, 2451 USA
Medical Center Dr., Mobile, AL 36617, USA.

Email: bomar@health.southalabama.edu

<https://cardiofellows.com/newsletter-july-2023.html>

References

1. Mattu A, Brady WJ, Perron AD. Electrocardiographic manifestations of hypothermia. *Am J Emerg Med.* 2002 Jul;20(4):314-26.
2. Alhaddad IA, Khalil M, Brown EJ Jr. Osborn waves of hypothermia. *Circulation.* 2000 Jun 27;101(25):E233-44.
3. Hudzik B, Gasior M. J-waves in hypothermia. *CMAJ.* 2017 Nov 27;189(47):E1461.
4. OSBORN JJ. Experimental hypothermia; respiratory and blood pH changes in relation to cardiac function. *Am J Physiol.* 1953 Dec;175(3):389-98.
5. Yan GX, Antzelevitch C. Cellular basis for the electrocardiographic J wave. *Circulation.* 1996 Jan 15;93(2):372-9.

KEYWORDS: Hypothermia; Electrocardiography; Osborn Waves.

Reference this article as:

Ur Rahman M, Riad M, Shah N, Mulyala R, Malozzi C, Omar B. Monstrous Osborn Waves: *A Frigid Demise!* Cardiofel Newslet 2023. July; 6(7):19 – 20.