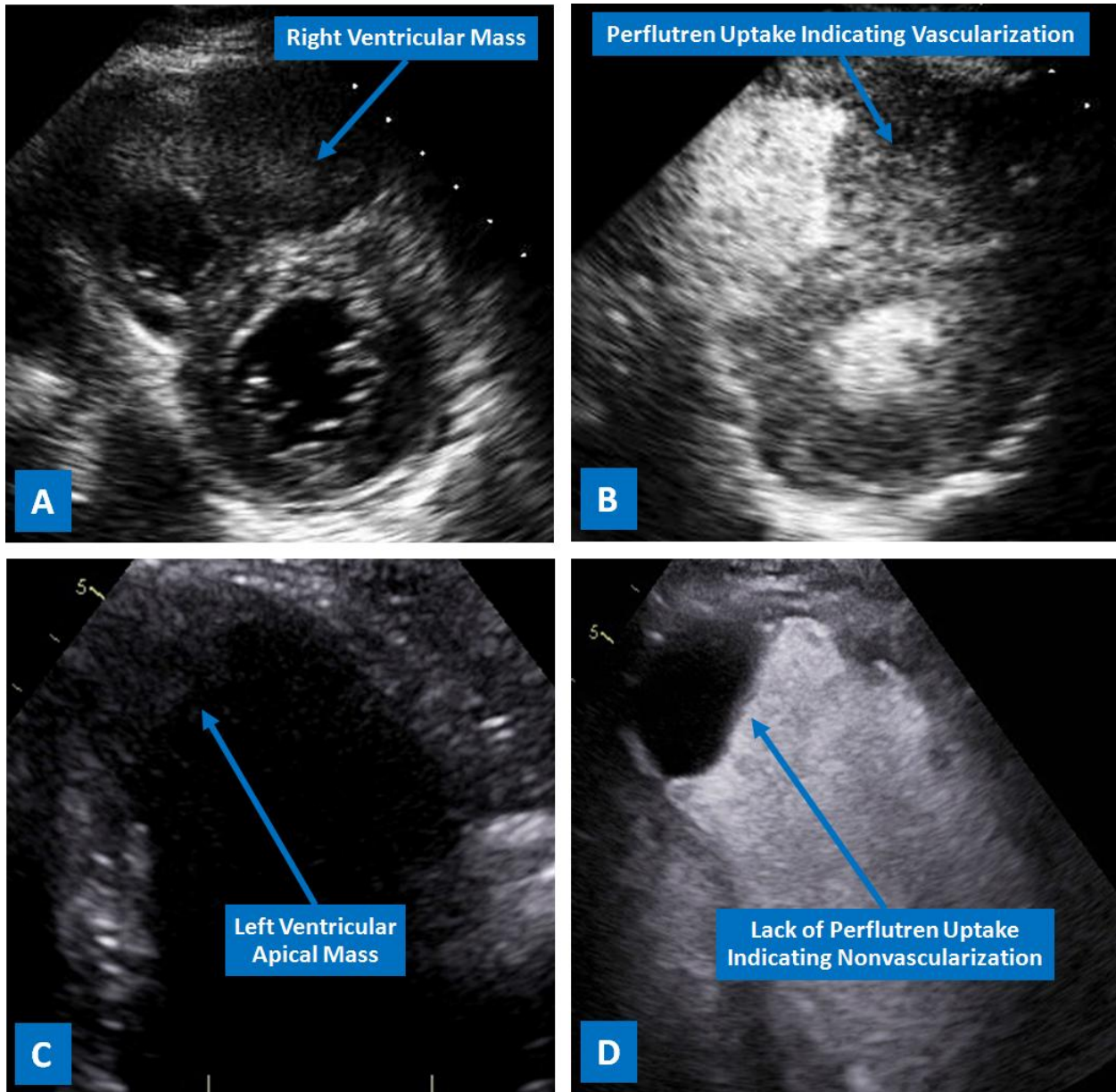


### Tumors Uptake Microbubbles..Gee Fizz!

Landai Nguyen, D.O.<sup>a,b</sup>, Sarina Sachdev, M.D.<sup>a</sup>, Sajjad Ahmad, M.D.<sup>a</sup>, Farnoosh Rahimi, M.D.<sup>a</sup>,  
 Barbara Burckhardt, M.D.<sup>a</sup>, Christopher Malozzi, D.O.<sup>a</sup>, Bassam Omar, M.D., Ph.D.<sup>a</sup>



### Description

Intracardiac masses not only can be poorly visualized by transthoracic echocardiography, but can also be difficult to characterize based on

their appearance only [1]. In the figure, the mass seen within the right ventricle on the parasternal short axis view of a 2-D echocardiogram (A)

readily uptakes perflutren microbubbles (Definity), indicating its vascularity (tumor). In contrast, the left ventricular mass (C) seen on the apical 2-chamber view does not uptake microbubbles (D) indicating lack of vascularity (thrombus). Contrast echo plays an essential role in endocardial border delineation [2], in addition to characterization of cardiac masses [3], especially in difficult to image patients [4].

---

Manuscript submitted October 16, 2018, accepted October 18, 2018.

a Division of Cardiology, University of South Alabama, Mobile, AL, USA

b Corresponding Author: Landai Nguyen, DO. Division of Cardiology, University of South Alabama, 2451 USA Medical Center Dr., Mobile, AL 36617, USA.

Email: landai@health.southalabama.edu

<https://cardiofellows.com/newsletter-october-2018.html>

---

### **References:**

1. Mankad R, Herrmann J. Cardiac tumors: echo assessment. *Echo Res Pract*. 2016 Dec;3(4):R65-R77..
2. Kaufmann BA, Wei K, Lindner JR. Contrast echocardiography. *Curr Probl Cardiol*. 2007 Feb;32(2):51-96.
3. Kirkpatrick JN, Wong T, Bednarz JE, et al. Differential diagnosis of cardiac masses using contrast echocardiographic perfusion imaging. *J Am Coll Cardiol*. 2004 Apr 21;43(8):1412-9.
4. Daniel GK, Chawla MK, Sawada SG, et al. Echocardiographic imaging of technically difficult patients in the intensive care unit: use of optison in combination with fundamental and harmonic imaging. *J Am Soc Echocardiogr*. 2001 Sep;14(9):917-20.

---

**KEYWORDS:** Cardiac Tumor; Contrast Echocardiography; Cardiovascular Disease

### **Reference this article as:**

Nguyen L, Sachdev S, Ahmad S, Rahimi F, Burckhardt B, Malozzi C, Omar B. Tumors Uptake Microbubbles..Gee Fizz! *Cardiofel Newslet* 2018 October;1(4):25-26.