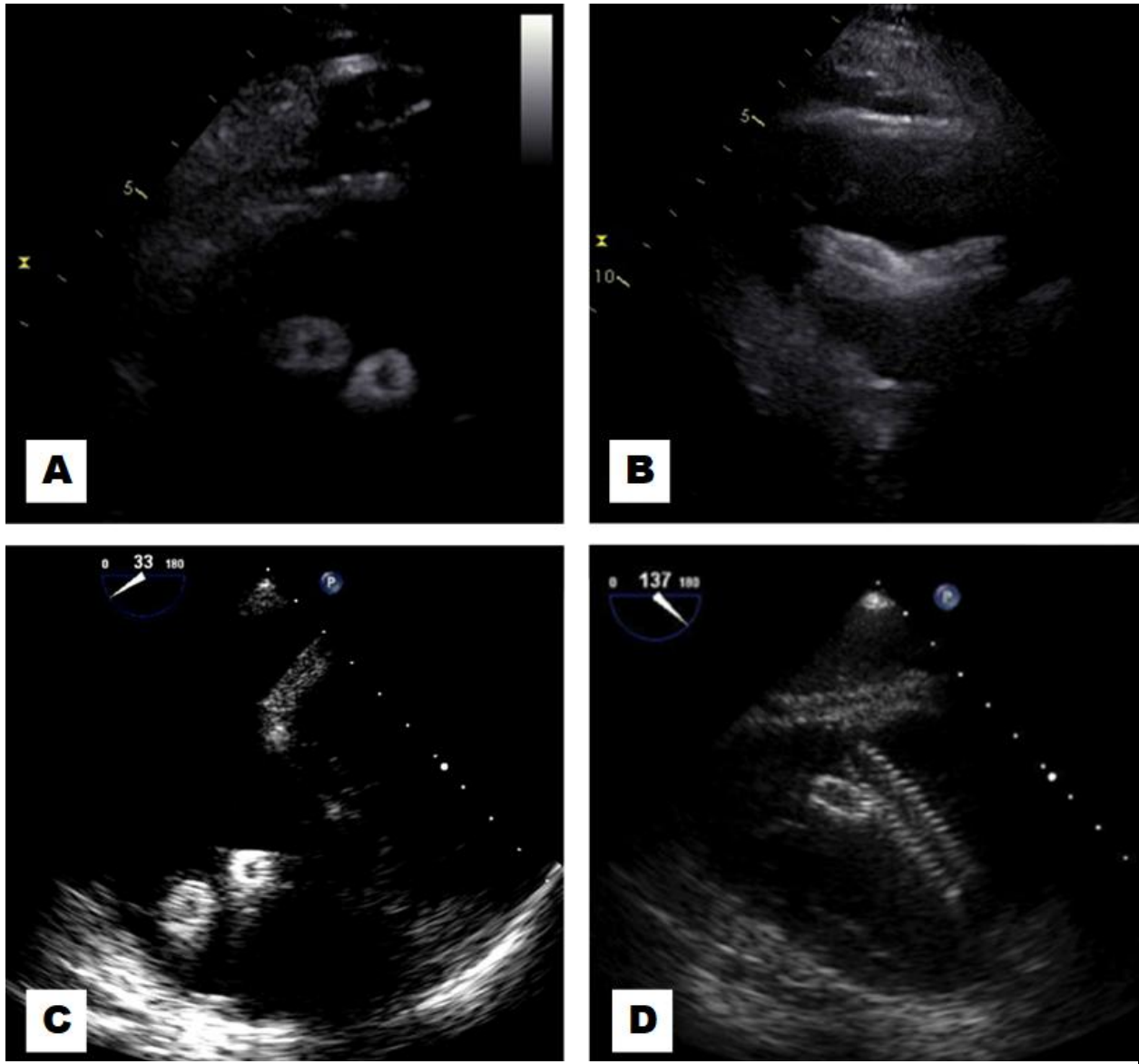


Lost Stents..Peek-a-Boo!

Landai Nguyen, D.O.^{a,b}, Sarina Sachdev, M.D.^a, Hassan Tahir, M.D.^a, Farnoosh Rahimi, M.D.^a,
Barbara Burckhart, M.D.^a, Christopher Malozzi, D.O.^a, Bassam Omar, M.D., Ph.D.^a, G. Mustafa Awan, M.D.^a



Description

Lost vascular stents following endovascular repair of an arteriovenous dialysis graft were incidentally found peeking through the right ventricular (RV) inflow views on transthoracic (A) and transesophageal (C) echocardiography in

short axis. Long axis transthoracic views (B) showed the stents crossing one another, and transesophageal (D) views showed the zipper-like appearance of the vascular stents at the RV inflow adjacent to the tricuspid valve. Vascular

stents are increasingly utilized for endovascular interventions in dialysis grafts [1], including hybrid grafts [2]. This comes at an increased risk of acute and long-term complications such as stent fracture or migration [3]. Although a wait-and-watch approach is initially prudent, there are a number of bail-out interventional procedures available [4].

Manuscript submitted October 4, 2018, accepted October 5, 2018.

a Division of Cardiology, University of South Alabama, Mobile, AL, USA

b Corresponding Author: Landai Nguyen, DO. Division of Cardiology, University of South Alabama, 2451 USA Medical Center Dr., Mobile, AL 36617, USA.

Email: landai@health.southalabama.edu

<https://cardiofellows.com/newsletter-october-2018.html>

References:

1. Shemesh D, Goldin I, Olsha O. Stent grafts for treatment of cannulation zone stenosis and arteriovenous graft venous anastomosis. *J Vasc Access*. 2017 Mar 6;18(Suppl. 1):47-52.
 2. Gomez LF, Peden EK. Description and early outcomes of the hybrid graft for dialysis. *J Vasc Access*. 2017 Mar 6;18(Suppl. 1):64-67.
 3. Ho JM, Kahan J, Supariwala A, et al. Vascular stent fracture and migration to pulmonary artery during arteriovenous shunt thrombectomy. *J Vasc Access*. 2013 Apr-Jun;14(2):175-9.
 4. Sequeira A. Stent migration and bail-out strategies. *J Vasc Access*. 2016 Sep 21;17(5):380-5.
-

KEYWORDS: Stents; Echocardiography; Cardiovascular Disease

Reference this article as:

Nguyen L, Sachdev S, Tahir H, Rahimi F, Burckhardt B, Malozzi C, Omar B, Awan GM. Lost Stents..Peek-a-Boo! *Cardiofel Newslet* 2018 October;1(4):23-24.